

Netherton's Syndrome: A Case Report

Nidal A. Obaidat, MD, Faten Al-Awaysheh, MD, and Rahmeh Fayez*, MD

*Department of Dermatology and Pediatrics
Prince Hashem Bin Al-Hussein Hospital
Zarqa, Jordan.*

Abstract

We report a case of a 12.5 years old male patient who presented to the dermatology clinic complaining of pruritic scaly dry skin and sparse brittle hair. Clinical and laboratory assessment revealed ichthyosis linearis circumflexa, trichorrhexis and atopy. These findings fit the diagnosis of Netherton's syndrome. Family history is also positive for the same disease.

Netherton's Syndrome (NS) is a rare autosomal recessive disorder, first described by Netherton in 1958 in a girl with erythematous scaly dermatitis who had 'bamboo-like nodes' in her sparse fragile hairs.¹ The classical triad of clinical features includes ichthyosis, hair shaft abnormalities and atopic diathesis.^{2,3} The disease has an estimated incidence of 1 in 100,000.² Only three cases have been published from the Arab World,^{4,5,6} and to the best of our knowledge, our case is the first to be published from Jordan.

Few days after birth, he developed skin erythema and scaliness, which became profound at the age of 2 months when he developed erythroderma and dehydration. He was admitted to hospital and given the appropriate care.

At the age of 1 year, the erythema disappeared except for residual erythematous element on the face. At that time, more characteristic skin lesions started to develop in the form of polycyclic erythematous scaly eruption mainly on the trunk.

His family also complains that he is small in body-built, and that his hair is sparse, short, spiky and slowly growing. His medical history includes bronchial asthma and recurrent sinopulmonary infection. His school performance is good. He has a positive family history with two brothers having a similar condition: one brother aged 18 years and the other is three years old. Three other cousins also have the same disease, as outlined in the family pedigree (Figure 1).

(JMJ 2005; Vol. 39 (2): 165- 170)

Received

October 7, 2004

Accepted

August 16, 2005

Keywords

Netherton's syndrome, case report.

Case Report

A 12.5 year old Jordanian male child presented to the dermatology clinic at Prince Hashem Bin Al-Hussein Hospital in July 2004, complaining of facial erythema, generalized itchy scaly skin rash and sparse brittle hair since early childhood. The patient was born to consanguineous marriage. He was a product of full term smooth pregnancy with normal birth weight and length.

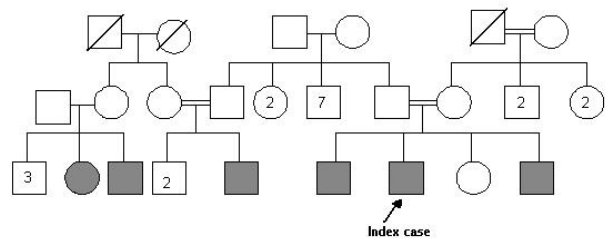


Figure 1: Pedigree of the patient's family.

Squares represent male family members and circles female family members. A slash indicates that the person has died. A double line indicates a consanguineous marriage. Open symbols represent healthy persons, solid symbols patients with Netherton's Syndrome.

Correspondence should be addressed to:

Rahmeh Fayez, MD
P.O.Box 6488, Zarqa 13115- Jordan.
Email: rahmehfyz@yahoo.com.

JORDAN MEDICAL JOURNAL, VOL.39.NO. (2) NOV 2005

Clinical Examination: On presentation, the patient was consumed with itching. He had decreased growth parameters: a weight of 29 kg and a height of 138 cm, both falling below the 5th percentile on growth chart. He also had short, lusterless, sparse, beaded and easily broken hair with sparse eyebrows and eye lashes as well, *figure 2*. Seborrheic -like scales and erythema of the face were also noted. His body was covered by polycyclic, serpiginous, erythematous plaques with double-edged scales along the margin (which is called ichthyosis linearis circumflexa, ILC), *figure 3a*. Flexural lichenification was also evident. Histological examination of lesional skin showed features typical of ILC: (parakeratosis, marked psoriasiform acanthosis and papillomatosis of the epidermis, with perivascular mixed cell infiltrates in the papillary dermis), *figure 3b*.

Laboratory Findings: Light microscopy of scalp and eyebrow hair showed trichorrhexis invaginata and pili torti, *figure 4* (a and b).

Complete blood count showed a White Blood Cell count (WBC) of 9.1×10^9 /L, with moderate eosinophilia at 7.3% of WBC. Normal eosinophil count is up to 4%.

His hemoglobin level was 12.9 g/dl, with normocytic normochromic red blood cells.

The erythrocyte sedimentation rate was 10 ml in the first hour.

Fasting blood sugar, liver enzymes, blood urea nitrogen, serum creatinine and urinalysis were all normal. Serum Zinc level was 11 micromol/ L (normal: 7-18 micromol/L). Arterial blood gas analysis was within normal for all parameters and blood ammonia level was 0.6 micrograms/mL (normal level is up to 0.8 micrograms/mL).

Immunoglobulins (Ig) serum levels showed increase in IgE level (IgE: 530 IU/ml, normal level: below 100 IU/ml). Other Ig levels were all within normal range: IgG: 1247 mg/L (700-1600), IgA: 139.6 mg/L (70-400), IgM 75.66 mg/L (40-230).

RAST (Radio- Allergosorbent- Test) revealed that the patient is allergic to many substances, including: grass, brich, ragweed, dermatophagoid pt., dermatophagoid farina and plantain. He was also shown to be sensitive to olive, wheat, rice and rye as well as hazelnut, almonds, tomato, carrots and potatoes.

Urine chromatography for amino acids and other organic acids was negative.

Management: The patient has been started on regular antihistamines (hydroxyzine hydrochloride and loratadine), emollients and keratolytics (5% lactic acid). Mild topical steroids were prescribed to be used intermittently for facial lesions. Most recently, he was started on topical pimecrolimus, which is showing promising symptomatic relief.

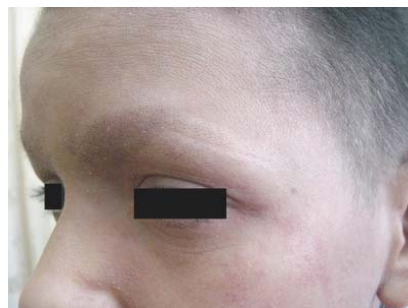

Figure 2: Short, lusterless, and sparse hair.

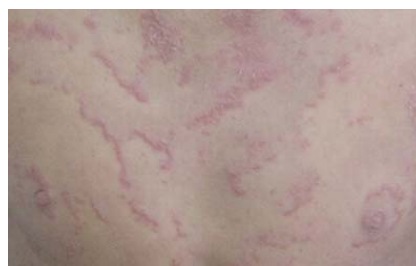

Figure 3a: Ichthyosis linearis circumflexa over the trunk.

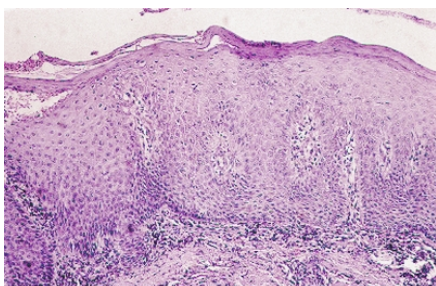


Figure 3 b: Photomicrograph of ILC (hematoxylin and eosin stain, x20).

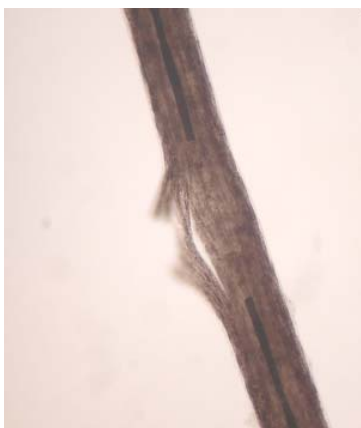

Figure 4 a: Hair shaft defect seen by light microscopy: trichorrhexis.



Figure 4 b: Hair shaft defect seen by light microscopy: pili torti.

Discussion

Netherton's Syndrome is a rare autosomal recessive disorder with variable expression, mainly affecting females.² The gene involved in the pathogenesis of NS (SPINK5 gene) has been mapped by linkage analysis and homozygosity, gene locus is on chromosome 5q32. This gene encodes serine protease inhibitor called LEKTI (Lymph-Epithelial-Kazal-Type Inhibitor), which is expressed in epithelial and lymphoid tissues.⁷ Different mutations have been described that lead to impaired proteolysis and so keratinocyte cornification and differentiation resulting in skin barrier defect. LEKTI might also be directly involved in the specific and innate immune system. The availability of molecular data opened the door for molecular diagnosis of NS and successful prenatal testing was achieved.^{8,9}

Patients with NS, like our patient, usually present with generalized erythroderma shortly after birth. The affected neonates are at risk of hypernatremic dehydration, temperature instability and sepsis. Another reported complication during the neonatal period is dermopathic enteropathy that manifests as diarrhea and failure to thrive even with appropriate dietary supplements. Jejunal villous atrophy was reported in one case out of three cases in one study which resolved spontaneously at the age of 10 months.¹⁰ At the neonatal stage, the diagnosis is difficult (especially in the absence of family history) because of the absence of characteristic features and because of the presence of numerous underlying causes for neonatal erythroderma.¹¹ Gene analyses can offer help in those cases.

ILC is a characteristic migratory polycyclic or annular plaques with double-edged scales and it is pathognomonic for NS. Although this disease is undoubtedly a congenital keratinization disorder, it has clinical and histological similarities to psoriasis.¹² Trichorrhexis Invaginata (TI) (bamboo hair = ball-and-cup hair) results from invagination of the distal part of the hair shaft (ball) into the proximal part (cup).

This invagination occurs at site of intermittent keratinization defect of the hair cortex that makes cortical cells soft.¹³ Bamboo hair usually breaks off at a length of 3-4 cm, and usually only a small number of hairs show clear changes so multiple examination is needed. Eyebrow and eyelashes may develop TI even earlier than scalp hair so they are a better choice for sampling.¹⁴ Other hair shaft defects (like pili torti seen in our patient) may be seen as well.

Atopic dermatitis is present in all cases of NS, and most cases have other atopic features like asthma, hay fever, high IgE, eosinophilia and food allergy.^{2, 3} Other reported abnormalities in cases of NS including growth retardation, mental retardation, selective antibodies deficiency to bacterial polysaccharides¹⁵ and aminoaciduria.

The main clinical diagnosis in our case was Netherton syndrome (ichthyosis linearis circumflexa in association with atopic eczema and hair shaft defects), which was confirmed by histological examination and laboratory investigations. The differential diagnosis in our patient included erythrodermic atopic and seborrheic dermatitis, psoriasis, nonbullous ichthyosiform erythroderma, zinc/biotin deficiency, protein metabolic disorders, pemphigus foliaceus, congenital erythroderma, erythrokeratoderma, hyper IgE syndrome and other immune deficiency syndromes.³ These diagnoses were ruled out in our case after appropriate laboratory investigations and in view of the patient's clinical setting.

Treatment of NS is mostly symptomatic and is aimed at the atopic dermatitis as well as the ichthyotic skin. It is very important to treat each patient according to his clinical presentation, as the clinical features of the disease are varied according to the age: infancy, childhood, and adulthood.

On the whole, emollients, keratolytics and antibiotics are still the mainstay of treatment in patients with NS. In the neonatal period, it is vital to prevent dehydration, temperature instability and infection. If any of these complications occur, it should be treated promptly.^{2, 16}

Management of atopic dermatitis should start with an assessment of the patient's individual needs according to their age, sex, social environment, sites of involved skin and severity of disease. The child with a topic dermatitis should wear cotton clothes, and should avoid synthetics and wools, which irritate the skin. Keeping the skin moist is extremely important in managing eczema because the skin is so dry. Atopic dermatitis is characterized by its inherent itch. Antihistamines (e.g. chlorpheniramine maleate, and hydroxyzine hydrochloride) have a role in management because they help the child sleep and break the itch-scratch cycle, if given at a sufficiently high dosage at bedtime.

The goal of treatment of atopic dermatitis is to relieve the itching and to flatten the lichenified lesions. Topical corticosteroids are the gold standard for treating eczema.¹⁶ However, the long term use of topical steroids is a matter of controversy as they may lessen the facial erythema but there is increased risk of systemic absorption because of the defective skin barrier, especially in infants and young children, and when large areas of the body are affected. Therefore, the object of treatment should be to use the lowest potency steroids that achieve the treatment goal. New topical immunomodulators offer an attractive supplement or alternative in certain circumstances. Foods that are known to cause an allergic skin reaction in a specific patient should be avoided. As localized bacterial infection is the most common complication of eczema, any signs of skin infection should be treated promptly, usually by anti-staphylococcal topical and/or systemic antibiotics.^{2, 16}

Treatment of the ichthyotic skin is aimed at decreasing the signs and symptoms by hydration, lubrication, and keratolysis. The affected skin has a decreased barrier function and increased transepidermal water loss. Thus, the main approach to treatment includes hydration of the skin followed immediately by the application of lubricants to retain the hydration and softening and to prevent evaporation. Treatment regimens are variable and are in no way restrictive. They may include topical agents, oral medications and/or a combination.¹⁷

Keratolytic creams and lotions used for ichthyosis may contain 10–20% urea, propylene glycol, alphahydroxy acids, or salicylic acid. However, because of the impaired barrier function in ichthyosis, a widespread use of topical salicylic acid or urea over large areas of body surface can lead to possible systemic absorption and toxicity. These preparations are better avoided in infants and young children.

Topical retinoids like tretinoin and tazarotene are beneficial in the treatment of ichthyosis but can be irritating in some patients. However, patients may complain of increased irritation as well as flares of their associated/concomitant atopic dermatitis. Systemic retinoids are not usually helpful as they may cause deterioration of the skin lesions, although there is one report of response to low dose acitretin.¹⁰ Topical calcipotriol, a synthetic vitamin-D₃ derivative, inhibits hyperproliferation and stimulates differentiation of keratinocytes. It has been reported to be used successfully in one patient, but long term efficacy and safety in NS should be assessed before adopting the treatment, as there may be a risk of hypercalcemia with the use of topical calcipotriol, especially when large areas of the body are involved.¹⁷ PUVA therapy (psoralen plus ultraviolet light A) has been reported to be beneficial in one patient with NS.¹⁸

Topical tacrolimus and pimecrolimus are immunomodulatory drugs successfully used for atopic dermatitis and tacrolimus which have been reported to be useful in patients with NS and in atopic dermatitis for children as young as 2 years of age.¹⁹ Dramatic clinical improvement using 0.1% tacrolimus ointment has been reported in patients with isolated ichthyosis linearis circumflexa and as part of Netherton syndrome. Systemic absorption occurred in the treated children, however, and tacrolimus blood levels were within or above the established therapeutic trough range for oral tacrolimus, but no signs or symptoms of toxicity developed.²⁰ Therefore, the dosage and application regimen of these drugs in patients with NS should be further clarified.

In conclusion, our case of Netherton's syndrome highlights the need for proper follow up and investigation in all pediatric patients presenting with seemingly resistant or unusual dermatitis-like skin lesions. New therapies may offer in the future some relief to the affected patients, and new laboratory methods promise prenatal diagnosis in families with members affected by NS.

References

1. Netherton EW. A unique case of trichorrhexis nodosa (bamboo hair). *Arch Dermatol.* 1958; 78:483-487.
2. Krafchik BR. What syndrome is this? Netherton's Syndrome. *Pediatr Dermatol.* 1992; 9:157-160.
3. Griffiths WA, Judge MR, Leigh IM. Disorder of keratinization. In: Champion RH, Burton JL, Burns DA, Breathnach SM. *Textbook of dermatology*, 6th edition, Blackwell Science Ltd, United Kingdom. 1998; 1511.
4. Mégarbané H, Tomb R, Mégarbané A, and Hovnanian A. First Report of Netherton's Syndrome in a Lebanese Child.
http://www.idi.it/did/congr/siderp_pdf/abstracts/poster/50%20Poster%20-%20Merarbane.pdf.
5. Ibrahim G, Jameeleh K, Hassan G. Netherton syndrome. *SKIN med.* 2003; 2: 387-389.
6. Khatri M, Shafi M. Netherton's Syndrome. *Indian Journal of Dermatology, Venereology and leprology.* 1989; 55:135-136.
7. Chavanas S, Bodemer C, Rochat A, et al. Mutation in SPINK5, encoding a serine protease inhibitor, cause Netherton Syndrome. *Nat Genet.* 2000; 25:141-142.
8. Sprecher E, Chavanas S, DiGiovanna JJ, et al. The spectrum of pathogenic mutation in SPINK 5 in 19 families with Netherton Syndrome: Implications for mutation detection and first case of prenatal diagnosis. *J Invest Dermatol.* 2001; 117: 179-187.
9. Muller FB, Hauber I, Berg D, et al. Genetic analysis of a severe case of Netherton Syndrome and application for prenatal testing. *Br J Dermatol.* 2002; 146: 495-499.
10. Judge MR, Morgan G, Harper JI. A clinical and immunological study of Netherton Syndrome. *Br J Dermatol.* 1994; 131: 615-621.
11. Pruszkowski A, Bodemer C, Fraitag S, Teillac-Hamel D, Amoric J, Prost Y. Neonatal and Infantile Erythroderma. *Arch Dermatol.* 2000; 136: 875-880.
12. Yoshiike T, Manabe M, Negi M, and Ogawa H. Ichthyosis linearis circumflexa: morphological and biochemical studies. *Br J Dermatol.* 1985; 112: 227-283.
13. Abell E. Inflammatory Disease of the Epidermal Appendages and of Cartilage. In: Elder D, Elentisas R, Jaworsky C, Johnson B. *Histopathology of the Skin*, 8th edition, Lippincott-Raven, United State of America. 1997; 409.
14. Powell J, Dawber RP, Ferguson DJ, Griffiths WA. Netherton's Syndrome: Increased likelihood of diagnosis by examining eyebrow hairs. *Br J Dermatol.* 1999; 141: 544-546.
15. Stryk S, Siegfried EC, Knutsen AP. Selective Antibody Deficiency to Bacterial polysaccharide Antigens in Patients with Netherton Syndrome. *Pediatr Dermaol.* 1999; 16: 19-22.
16. Krafchik BR. The use of topical steroids in children. *Seminars in Dermatology.* 1995; 14: 70.
17. Rubeiz N and Kibbi A. Management of ichthyosis in infants and children. *Clinics in Dermatology.* 2003; 21: 325- 328.
18. Nagata T. Netherton's syndrome which respond to photochemotherapy. *Dermatologica.* 1980; 161: 51-56.
19. Kang S, Lucky AW, Pariser D, et al. Long-term safety and efficacy of tacrolimus ointment for the treatment of atopic dermatitis in children. *J Am Acad Dermatol.* 2001; 44: S58.
20. Allen A, Siegfried E, Silverman R, et al. Significant absorption of topical tacrolimus in 3 patients with Netherton Syndrome. *Arch Dermatol.* 2001; 137: 747-750.

متلازمة نيزرتون : حالة مرضية

د. نضال عبيدات، د. فاتن العوايشه، د. رحمه فايز

مستشفى الامير هاشم بن الحسين

الزرقاء - الأردن

ملخص:

هذه السمات تتوافق مع تشخيص متلازمة نيزرتون. السيرة المرضية للعائلة أظهرت وجود حالات أخرى في العائلة تعاني من نفس المرض.

الكلمات الدالة:

متلازمة نيزرتون ، حالة مرضية.

نقدم هنا مريضاً يبلغ من العمر اثني عشر عاماً ونصف، قدم إلى عيادة الجلدية يشكو من جفاف وتقشير في الجلد مصحوباً بحكة جلدية بالغضافة إلا أن شعره هش وخفيف. بالفحص السريري والمخبري تبين أن المريض يعاني من الداء الحرشفي الخطي الدائري مع هشاشه في الشعر وإكزيما لا نوعيه (أتوبيه).